Case Report

Open Access Journal of
Biomedical Science
ISSN: 2690-487X

Electrocardiographic Signs and Acute Pericarditis in Renal Failure with Past COVID-19 Pneumonia

Yasser Mohammed Hassanain Elsayed*

Kafr-El-Bateeck Central Hospital, Egyptian Ministry of Health (MOH), Egypt

ABSTRACT

Rationale: Acute pericarditis is a serious cardiovascular disease characterized by an inflammation of the pericardium. Chronic renal failure and COVID-19 infection are known implicated causes. Assortment of electrocardiographic signs such as can be detected in acute pericarditis. Patient concerns: A middle-aged Parking-Officer heavy smoker married Egyptian male patient was admitted to the intensive care unit with severe acute chest pain and acute pericarditis. Diagnosis: Acute Pericarditis in chronic renal failure on hemodialysis with past COVID-19 pneumonia. Interventions: Electrocardiography and echocardiography. Outcomes: Gradual dramatic clinical and electrocardiographic improvement had happened. Lessons: Varieties of electrocardiographic signs of acute pericarditis in chronic renal failure on hemodialysis with past COVID-19 pneumonia are newly described. Chronic renal failure and past COVID-19 pneumonia may be implicated in the current acute pericarditis.

KEYWORDS: Pericarditis; Signs; Chronic renal disease; Hemodialysis; COVID-19; Chest pain

ABBREVIATIONS: AMI: Acute Myocardial Infarction; CBC: Complete Blood Count; CRF; Chronic Renal Failure; ECG: Electrocardiography; ICU: Intensive Care Unit; IV: Intravenous; NSR: Normal Sinus Rhythm; O2: Oxygen; SGOT: Serum Glutamic-Oxaloacetic Transaminase; SGPT: Serum Glutamic-Pyruvic Transaminase; STEMI: ST-Segment Elevation Myocardial Infarction; VR: Ventricular Rate; MOH Ministry of Health; V2-6: Precordial Leads

INTRODUCTION

Acute pericarditis is the most frequent pericardial disease. There are about 0.1% of hospital admitted patients and 5% of emergency admitted patients with chest pain irrelevant to myocardial infarction (MI) [1]. The etiological evaluations are mostly indecisive. Viral or idiopathic causes are common in immunocompetent cases. The other causes should not be neglected. Chronic renal failure (CRF) and COVID-19 infection are considered causes. Indeed, more than 95% of cases of acute pericarditis present with retrosternal acute, sharp, pleuritic chest pain. The pain commonly ameliorates in the sitting position or by leaning forward. This will diminish pressure on the parietal pericardium, but it is not alleviated with nitrates. However, acute pericarditis by itself confers low mortality. Patients with acute pericarditis should be treated empirically with nonsteroidal anti-inflammatory drugs (NSAIDs); [1]. Widespread concave ST-segment elevation is common throughout most of the limb leads (I, II, III, aVL, aVF) and precordial leads [V2-6]; [2]. Spodick's sign is statistically associated with pericarditis, but it is seen in 5% of patients with ST-segment elevation myocardial infarction (STEMI) [3]. ECG changes associated with Stage I pericarditis was first described by DH Spodick in 1974. The sign remained relatively unevaluated until a recent retrospective analysis in 2020. Witting et al, considered an ECG to show Spodick's sign when at least two leads had TP-segment down sloping of at least 1 mm3. Down sloping of the TP-segment was seen as an early ECG manifestation in ~30% of patients with pericarditis. It is best visualized in leads II and the lateral precordial leads4. The clinical significance of Spodick's sign is

Quick Response Code:

Address for correspondence: Yasser Mohammed Hassanain Elsayed, Kafr-El-Bateeck Central Hospital, Egyptian Ministry of Health (MOH), Egypt

Received: September 29, 2022 **Published:** October 26, 2022

How to cite this article: Elsayed Y.M.H. Electrocardiographic Signs and Acute Pericarditis in Renal Failure with Past COVID-19 Pneumonia. 2022- 4(5) OAJBS.ID.000505. **DOI:** 10.38125/OAJBS.000505

(a) Probable helpful discriminatory ECG sign between acute pericarditis and acute coronary syndrome.

(b) Witting revealed that Spodick's sign occurred in 29% of patients with pericarditis and 5% of patients with (OR 5.9)

(c) PR-segment depression alone can be a masquerader as it is seen in 12% of patients with STEMI

(d) A separate prospective study by Porela et al. revealed that PR-segment depression had a high sensitivity (88%) for myopericarditis but a low specificity [3,4].

The vertical height of the ST-segment elevation (from the end of the PR-segment to the J point) is measured and compared to the amplitude of the T-wave (ST-segment/T-wave ratio) in V6. If the ratio of > 0.25 suggests pericarditis but if < 0.25 suggests BER [3]. PR-segment depression is only reliably seen in viral pericarditis, not by other causes. It is often only an early transient phenomenon (lasting only hours). MI can also cause PR segment depression due to atrial infarction (or PR-segment elevation in aVR). ST-segment elevation in lead II>III lead was a distinguished sign [2].

CASE PRESENTATION

A 54-year-old Parking-Officer heavy-smoker married Egyptian male patient presented to the Emergency Department (ED) with acute severe chest pain and palpitations for about 48 hours. Chest pain was stabbing, sharp, retrosternal, pericardial, radiating to left shoulder, improved on sitting up, worsen in supine position and inspiration. Upon general physical examination, generally, the patient was anxious and distressed, with a regular pulse rate of VR of 100, blood pressure (BP) of 130/80mmHg, respiratory rate of 18 bpm, a temperature of 38.5 °C, and pulse oximeter of oxygen (O_2) saturation of 96%. He appeared normal body status.

Friction rub was listening on cardiac auscultation. No more relevant clinical data were noted during the clinical examination. The patient was admitted to the ICU with acute pericarditis. Initially, he was treated with O_2 inhalation (100%, by nasal cannula, 3L/min). Diclofenac sodium amp (75mg, BID) and colchicine tablets (500ug, BID) were the maintaining added to therapy. The initial complete blood count (CBC); Hb was 12.8 g/dl, RBCs; $4.61*10^3/mm^3$, WBCs; $7.46*10^3/mm^3$ (Neutrophils; 80.6 %, Lymphocytes: 10.2%, Monocytes; 7%, Eosinophils; 1.3% and Basophils 0.9%), and Platelets; $224*10^3/mm^3$. D-dimer was normal (0.150 ng/ml). CRP was high (17g/dl). SGPT (15U/L), SGOT (12U/L), and total bilirubin (0.8mg/dl) were normal. Serum albumen was normal (3.6gm/dl). Serum creatinine (8mg/dl) and blood urea (103mg/dl) were high. RBS was normal (120 mg/dl). Prothrombin time (13.8 Sec.) and INR (1.1) were normal. Plasma sodium (137mmol/L) and serum potassium (4.1mmol/L) were normal. Ionized calcium was slightly low (0.9mmol/L). The troponin test was positive (3.2 ng/dl). Serial ECG tracings were done. The initial ECG was done on the initial presentation showing sinus tachycardia (VR; 100), widespread concave upward ST-segment elevation, downsloping TP-segment (Spodick sign), ST-segment depression in aVR lead, PR-segment elevation in aVR lead, PR-segment depression in other leads, the ratio of ST-segment elevation to T-wave amplitude (in mm) in lead V6 more than 0.25, and the amplitude of ST-segment elevation (in mm) in lead II lead more than III lead (Figure 1A).

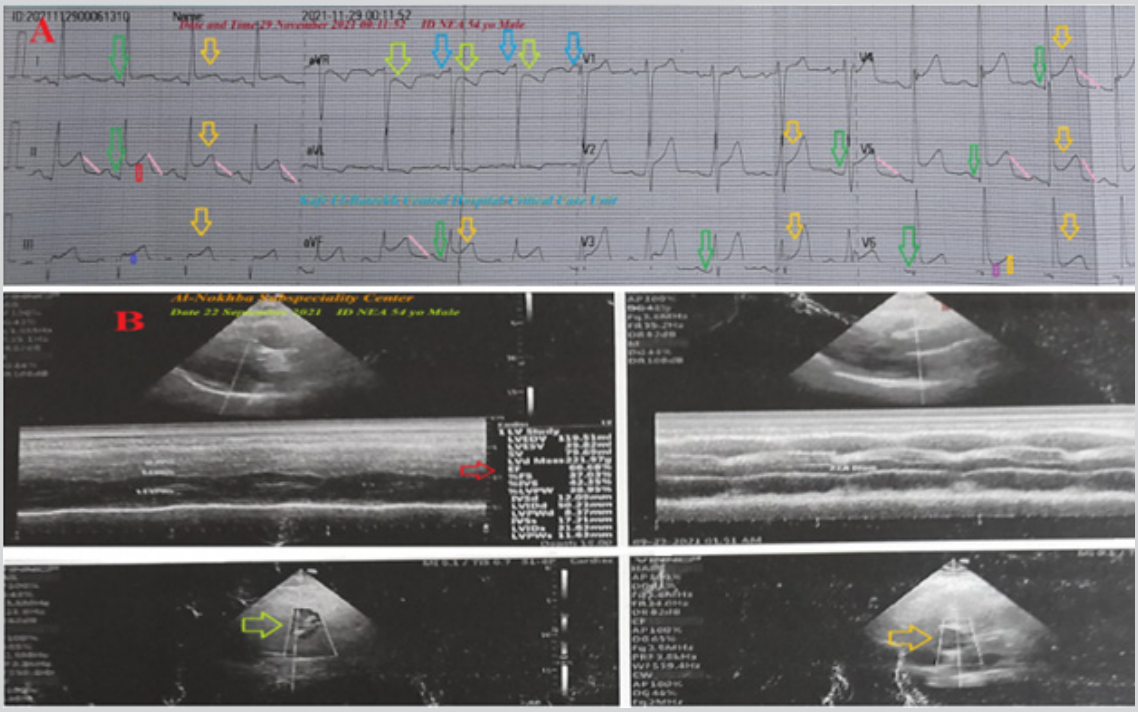

Figure 1: 1A-ECG tracing was done on the initial presentation showing sinus tachycardia (VR; 100), widespread concave upward ST-segment elevation (orange arrows), down sloping TP-segment (Spodick sign; rose arrows), ST-segment depression in aVR lead (lime arrows), PR-segment elevation in aVR lead (light blue arrows), PR-segment depression (green arrows) in other leads, the ratio of ST-segment elevation to T-wave amplitude (in mm) in lead V6 more than 0.25 (pink and golden rectangles), and the amplitude of ST-segment elevation (in mm) in lead II lead more than III lead (blue and red rectangles). 1B. Echocardiography w was done within a few weeks before this attack and showed concentric LVH, mild MR, and trivial TR (golden and lime arrows) with normal EF (66%; and red arrows).

The current echocardiography was done on the day of the presentation showing increased wall thickness, mild MR, and trivial TR with normal EF (55%). Previous echocardiography was done within a few weeks before this attack and showed concentric LVH, mild MR, and trivial TR with normal EF (66%) (Figure 1B). CXR- PA view, the plain film was done within 2 weeks before the ICU presentation showing bilateral basal vague ground-glass opacities in the healing stage of COVID-19 pneumonia (Figure 2A). ECG tracing was done within 3 months of the ICU the presentation showed normal sinus rhythm (NSR) of VR; 92 with the disappearance of all above changes. There is a Wavy triple sign (Yasser's sign) of hypocalcemia in aVR lead (Figure 2B). Acute pericarditis in chronic renal failure on hemodialysis with past COVID-19 pneumonia was the most probable diagnosis. Within 48 hours of the above management, the patient finally showed nearly clinical and heart rate improvement. The patient was discharged on the 2nd day and continued on diclofenac sodium tablets (25mg, TID) for two weeks and colchicine tablets (500µg, BID) for three months. Future cardiac follow-up was advised.

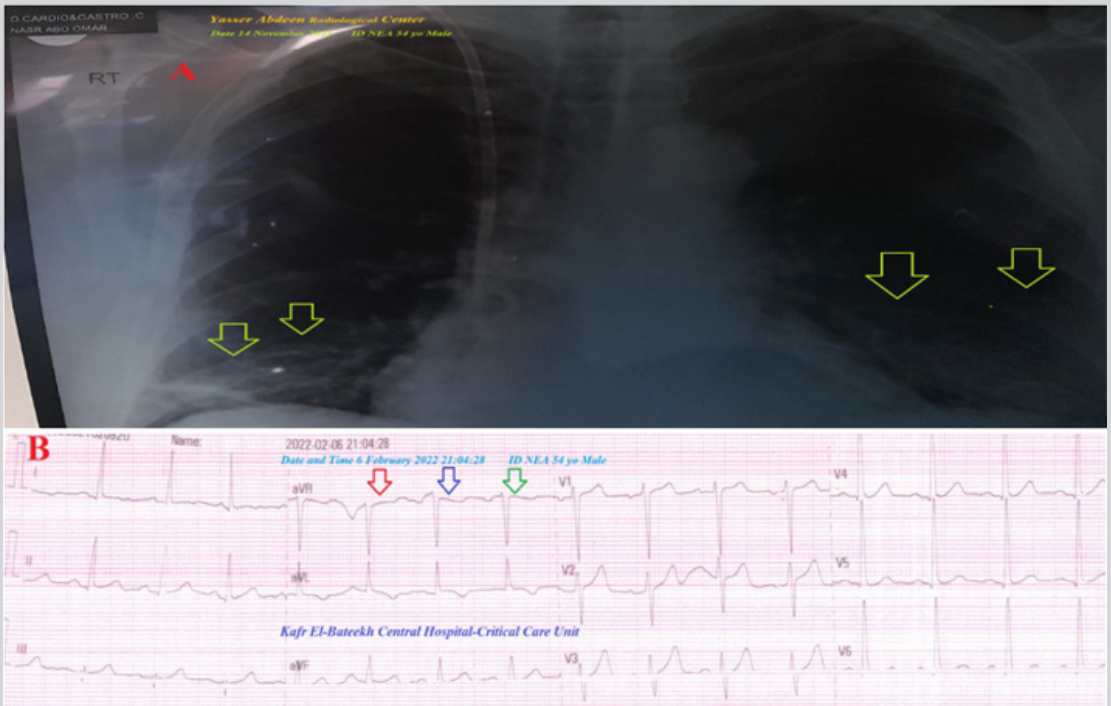

Figure 2: CXR- PA view, the plain film was done within 2 weeks before the ICU presentation showing bilateral basal vague ground-glass opacities in the healing stage of COVID-19 pneumonia (lime arrows). 2B. ECG tracing was done within 3 months of the ICU presentation showing normal sinus rhythm of VR; 92 with the disappearance of all above changes. There is a Wavy triple sign (Yasser's sign) of hypocalcemia in aVR lead (red, blue, and green arrows).

DISCUSSION

Overview

A middle-aged Parking-Officer heavy smoker married Egyptian male patient was admitted to the intensive care unit with severe acute chest pain and acute pericarditis.

The Objective Primary

for my case study was the presence of acute pericarditis in ESRD on hemodialysis with past COVID-19 pneumonia in the admitted ICU patient.

The Secondary Objective

for my case study was the question; How did you manage the case?

a. There was a history of acute chest pain was stabbing, sharp, retrosternal, pericardial, radiating to left shoulder, improved on sitting up, worsen in supine position and inspiration with heard friction rub on cardiac auscultation and characteristic ECG of acute pericarditis.

b. The presence of the initial ECG tracing showed Sinus tachycardia, widespread concave upward ST segment elevation, PR-segment depression, ST-segment elevation leads II lead >III, ST-segment depression in aVR, Spodick's sign, Checkmark ST-segment, convex ST-segment in V2 and V3, PR-segment elevation in aVR is seen in the current ECG. All these findings and signs are variably in acute pericarditis (Table 1); [5,6].

c. Myocardial infarction or ischemia and pulmonary embolism were the most probable electrocardiographic differential diagnosis for the current case study. But there are no pathologic Q-waves, convex regional ST-segment elevations, and reciprocal changes with myocardial ischemia or infarction. ECG findings are against the diagnosis of acute pulmonary embolism.

d. I can't compare the current case with similar conditions. There are no similar or known cases with the same management for near comparison.

e. The only limitation of the current study was the unavailability of pericardial biopsy.

Table 1: Electrocardiographic findings or signs of acute pericarditis [2,4-6].

Finding or Sign	Description	%	Significance	ECG
ST-segment elevation	• Diffuse concave upward ST elevation, except in leads aVR and V1 (usually depressed). • The degree of ST elevation is typically modest (0.5 – 1mm).	69.3	• Diffuse ST elevations can be seen in STEMI as well	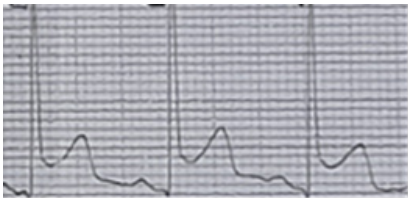
PR-segment depression	• PR-segment depressions in multiple leads	49.2	• In 80% of viral pericarditis. • PR depression alone can be a masquerader as it is seen in 12% of patients with STEMI. • It is often only an early transient phenomenon	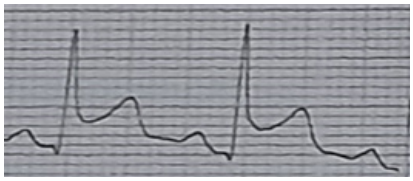
ST-segment elevation lead II lead >III	• The amplitude of ST-segment elevation (in mm) in lead II lead is more than III lead (> 0.25) Or • Vertical height of ST -segment from the end of PR segment to J point/ amplitude of T-wave	2	• It can be differentiated STEMI which is showing the opposite. (III lead is more than II lead) (< 0.25)	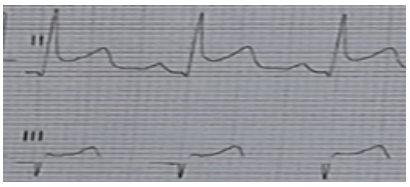
ST segment depression	• Reciprocal ST – segment depression in lead aVR (± V1)	12	• Characteristic ECG changes for acute pericarditis	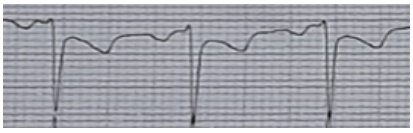
Spodick's Sign	• Downsloping of TP-segment, or entire QRSTP segment, particularly in Lead II • Spodick's sign when at least two leads had TP downsloping of at least 1 mm.	29	• Potential useful distinguishing ECG feature between acute pericarditis and ACS.	
Checkmark ST-segment	• QR-T complexes	7	• Checkmark sign can be seen in both pericarditis or STEMI, particularly if the patient has a wraparound LAD which supplies the inferior wall.	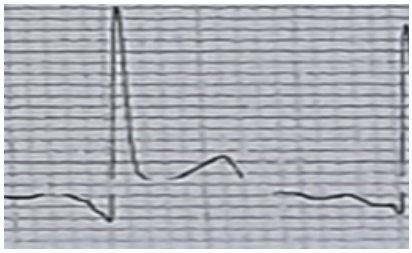
Convex ST-segment	• Convex upward of ST-segments	7	• Convex ST segments mainly can be seen in STEMI as well	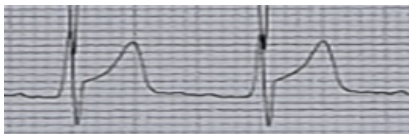
PR-segment elevation	• Pericarditis causes PR -segment elevation in lead aVR (± V1)	NA	• PR-segment elevation in aVR can be seen in STEMIs as well	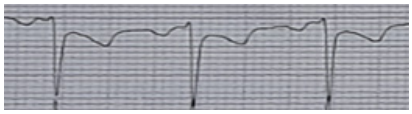
Sinus tachycardia	• It is common in acute pericarditis	NA	• It is due to pain and/or pericardial effusion	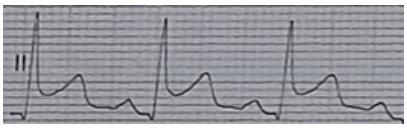

CONCLUSION AND RECOMMENDATIONS

Varieties of electrocardiographic signs of acute pericarditis in chronic renal failure on hemodialysis with past COVID-19 pneumonia are newly described. Chronic renal failure and past COVID-19 pneumonia may be implicated in the current acute pericarditis.

ACKNOWLEDGMENT

I wish to thank the nurse team of the intensive care unit in Kafr-El-Bateeck Central Hospital to give me extra copies of the ECG to help me.

REFERENCES

1. Snyder JM, Bepko J, White M (2014) Acute pericarditis: diagnosis and management. Am Fam Physician 89(7): 553-560.
2. Burns Ed, Buttner R (2021) Pericarditis ECG library.
3. Witting MD, Hu KM, Westreich AA, Tewelde S, Farzad A, et al. (2020) Evaluation of spodick's sign and other electrocardiographic findings as indicators of stemi and pericarditis. J Emerg Med 58(4): 562-569.
4. Buttner R, Cadogan M (2022) Spodick sign.
5. Spangler S (2019) Acute pericarditis. Medscape.
6. Yoffe M (2012) How to distinguish pericarditis from STEMI.