

# Urological Surgery Through Lumboscopic Access, What's New?

**Faruk Hernández Sampayo<sup>1\*</sup>, Jefferson David Jaimes Bautista<sup>2</sup>, Diana Marcela Hernandez Muñoz<sup>3</sup>, Paula Andrea Fernández Uribe<sup>4</sup>, Victor Ramon Mendoza Henriquez<sup>5</sup>, Dána Marcela Peñaranda Ramírez<sup>6</sup>, Olga Nataly Polania Pérez<sup>7</sup> and Israel Andrés Diaz Alvarado<sup>8</sup>**

<sup>1</sup>General Surgeon, Universidad Metropolitana de Barranquilla, Colombia

<sup>2</sup>General physician, Universidad Industrial de Santander, Bucaramanga, Colombia, <https://orcid.org/0000-0001-5042-9663>

<sup>3</sup>General physician, Universidad Industrial de Santander, Bucaramanga, Colombia, <https://orcid.org/0000-0002-9923-5840>

<sup>4</sup>General physician, Universidad Libre, Cali, Colombia

<sup>5</sup>General physician, Universidad del Magdalena, Colombia

<sup>6</sup>General physician, Fundación Universitaria de Ciencias de la Salud, Bogotá, Colombia

<sup>7</sup>Medical Student Universidad de Santander, Colombia, <https://orcid.org/0000-0003-4580-3678>

<sup>8</sup>General physician, Corporación Universitaria Rafael Núñez, Colombia

## ABSTRACT

**Background:** Retroperitoneal cysts are thought to be benign tumors of the retroperitoneum. To date, it is known that the treatment of choice for retroperitoneal cysts continues to be surgery or surgical excision of the cyst. Another of the urological conditions that require surgical intervention is the renal cyst as well as the ureteral lithiasis.

**Methodology:** A systematic review was carried out in various databases from January 2015 to July 2022; the search and selection of articles was carried out in journals indexed in English.

**Results:** The prioritization of surgeries that occurred in the COVID-19 pandemic are bladder cancer surgery, testicular cancer, kidney cancer, among others. The lumboscopic approach had its indications since 1999. At present, the lumboscopic approach has many therapeutic indications for various diagnoses, the most frequent being retroperitoneal cysts, renal cysts and ureteral lithiasis.

**Conclusion:** This review offers updated and detailed information on the benefits of the lumboscopic approach in urological surgeries, as well as reporting on the possible prioritization of urological surgeries in cases that require it, such as in this COVID-19 pandemic.

**KEYWORDS:** Urological surgery; Lumboscopy; Renal cysts; COVID-19

## INTRODUCTION

Retroperitoneal cysts are thought to be benign tumors of the retroperitoneum. They often reach large proportions before causing

any symptoms. These rare tumors are derived from remnants of the embryonic urogenital tract that includes tissues of epithelial and mesothelial origin [1]. To date, it is known that the treatment of

### Quick Response Code:



**Address for correspondence:** Faruk Hernández Sampayo, General Physician, Universidad Metropolitana de Barranquilla, Colombia

**Received:** August 25, 2022

**Published:** October 12, 2022

**How to cite this article:** Faruk HS, Jefferson DJB, Diana MHM, Paula AFU, Victor RMH, et al. Urological Surgery Through Lumboscopic Access, What's New?. 2022- 4(5) OAJBS.ID.000497. DOI: [10.38125/OAJBS.000497](https://doi.org/10.38125/OAJBS.000497)

choice for retroperitoneal cysts continues to be surgery or surgical excision of the cyst. Recurrence is very frequent in those cases in which an adequate excision is not performed. The most frequent symptoms associated with this condition are abdominal dilation, abdominal pain [1].

Another of the urological conditions that require surgical intervention is the renal cyst. A kidney cyst is the most common kidney injury. These are so ubiquitous that they are present in about 40% of patients who undergo imaging [2]. Kidney cysts can be the result of congenital or acquired disease. The acquired form is the most common. These can range from benign to malignant. Autosomal recessive kidney disease is caused by a mutation in the PKHD1 gene located on chromosome 6 that results in the formation of cysts in the collecting ducts. Multicystic dysplastic kidney disease is most commonly idiopathic [1,2]. The presence of acquired renal cysts increases with age. They are believed to be present in up to 5% of the general population. This prevalence increases to more than 25% in people older than 50 years. Kidney cysts can be diagnosed by ultrasound, computed tomography (CT), and magnetic resonance imaging (MRI) [2]. Treatment of childhood polycystic kidney disease is mainly supportive, with dialysis and transplantation, but in general, patients tend to have a poor prognosis. Multicystic dysplastic kidney disease has a controversial treatment of nephrectomy on the affected side [3]. Another of the pathologies that require a lumboscopic therapeutic approach is ureteral lithiasis. Ureterolithiasis is a worldwide disease that affects millions of people and represents a great economic burden. Therefore, this disease represents a significant burden for the health system. There is also an increasing incidence and prevalence of this disease [4].

## RESULTS

### Urological Surgeries and COVID-19

**Table 1:** Prioritization of urological surgeries in the COVID-19 pandemic.

Condition	Surgical procedure or recommended alternative treatment	Synthesis
Bladder cancer	Cystectomy for MIBC	Delaying cystectomy for MIBC for 90 days increases pN+ rate and is associated with higher pathologic stage
	Cystectomy for CIS refractory to third-line therapy.	cT1 tumors are understaged in up to 50% of cases, representing a significant risk of MIBC loss.
Testicular cancer	Orchiectomy for suspected testicular tumors	Orchiectomy is an outpatient procedure with potential OS benefit and should be prioritized
Kidney cancer	Nephrectomy for cT3+ tumors, including all patients with renal vein thrombi and/or IVC	More advanced kidney tumors, particularly with associated venous thrombi, can progress rapidly and create more complicated surgeries
Prostate cancer	Most prostatectomies should be delayed	Given the availability of other treatment modalities, these surgeries may be given a lower priority.
Upper tract urothelial carcinoma (UTUC)	Nephroureterectomy for high-grade and/or cT1+ tumors	A 3-month delay in surgery for UTUC has been associated with disease progression for all patients.
Adrenal tumors	Adrenalectomy for suspected adrenocortical carcinoma (ACC) or tumors >6 cm	Adrenal masses >6 cm are much more likely to harbor carcinoma
Urethral/penile cancer	Clinically invasive or obstructive cancers	Prevention of lymph node metastases can save the patient significant morbidity.
calculations or stones	For obstruction/infection	When possible, stents can be placed at the bedside
	Ureteral stent insertion	Nephrostomy tubes can be placed under local anesthesia, without the need for a ventilator
Fistula with pelvic sepsis	If there are systemic symptoms, diversion with catheters/drains or formal diversion of fecal flow	Fistula repairs are resource intensive and should be delayed when possible

Often, the etiology of a patient's kidney stones is unknown. Unless a patient passes a stone, she can retrieve it and send it for analysis, the components of the stone generally remain unknown. In most cases, only large or obstructive stones require surgical intervention [5]. According to epidemiology, many Americans will, at some point in their lifetime, experience the painful condition known as nephrolithiasis. This condition affects approximately 1 in 11 people in the US [6,7]. Given that these conditions, retroperitoneal cyst, renal cyst and ureteral lithiasis are the main diagnoses for which surgical intervention is performed by lumboscopic access, and the great incidence and prevalence that these diseases present, it is convenient to carry out this work, in order to provide updated and detailed information on the benefits of this procedure, as well as to inform about the possible prioritization of urological surgeries in cases that require it, such as in this COVID-19 pandemic.

## MATERIALS AND METHODS

A systematic review was carried out, PubMed, Scielo and ScienceDirect, among other journals, were the databases that we implemented in this work. The articles were selected in English, from the years 2015 to 2022. The DeCS and MeSH methodology was used to choose the keywords, within which we identified: Urological surgery; lumboscopy; kidney cysts; COVID-19. 98 original and review publications related to the subject studied were identified, 21 articles met the specified inclusion requirements, such as articles that were in a range not less than the year 2015, that were full text articles and that reported on the urological surgeries through lumboscopic access.

Due to the COVID-19 pandemic, we have been involved in various changes, some with positive effects and others with devastating effects. Urological surgery during the pandemic was also affected, due to the cancellation of elective surgeries to free up healthcare resources, as well as prioritizing other surgeries [7]. The choice of urgent or emergent surgeries that have yet to be performed will depend on capacity and demand but must also be balanced against the effects of delaying surgery. This is particularly true for patients with urologic cancers and complicated stones [8]. Previous data on delays in care is the current best guide by which

we can begin to select cases to prioritize in the face of acute decline in resources and diversion of operational resources to care for COVID-19 patients [9]. In Table 1 we can see the urological surgeries that were prioritized during this COVID-19 pandemic, as well as their possible alternative management. These recommendations, which can be applied in the current situation and in any future situation where ventilators and other OR resources are in short supply, prioritize moving forward where evidence suggests that even short-term delays can affect patient survival [9-12]; (Table 1).

### Urological Surgery Using the Lumboscopic Approach

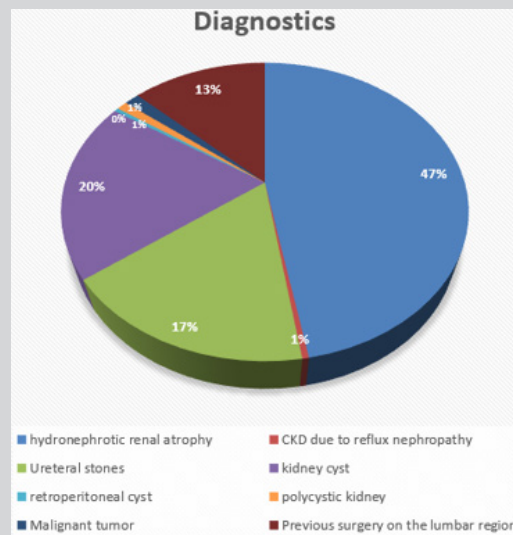


Figure 1: Main diagnoses for which lumboscopic access is indicated.

As is known, the lumboscopic approach had its indications since 1999, in the National Center for Minimal Access Surgery, but it was not yet fully applied in health centers, but it was since 2012, where a study was carried out where the feasibility of such access was demonstrated [13,14]. The first lumboscopic surgery was performed in Cuba in 1999, and in 2012 the advantages and feasibility of such access were developed. This caused a greater increase in the indications for the lumboscopic approach [15]. Currently, the lumboscopic approach has many therapeutic indications for various diagnoses. Image 1 shows the main diagnoses for which this type of surgery is implemented [15-17]. (Figure 1). Hydronephrotic renal atrophy was the main diagnosis, in most patients due to retrourethral lithiasis, followed by iatrogenic injury

to the ureter and stenosis of the ureteropelvic junction. Among the malignant tumors, two cavity tumors and one renal tumor were diagnosed. According to the classification of the American Society of Anesthesiology, we found that 29.3% of the patients presented an ASA I, 63.6% presented an ASA II and 7.1% of the patients presented an ASA III [16]. In Figure 2 we can see the surgical procedures that have been implemented through lumboscopic access [17-19]. To date, this type of procedure continues to present a moderate level of complexity, but compared to previous surgical procedures, there has been a decrease in complexity and in its complications. It has been seen that 22.8% of patients have low complexity, 73.9% have moderate complexity and 3.3% of patients have a high level of complexity [19]; (Figure 2).

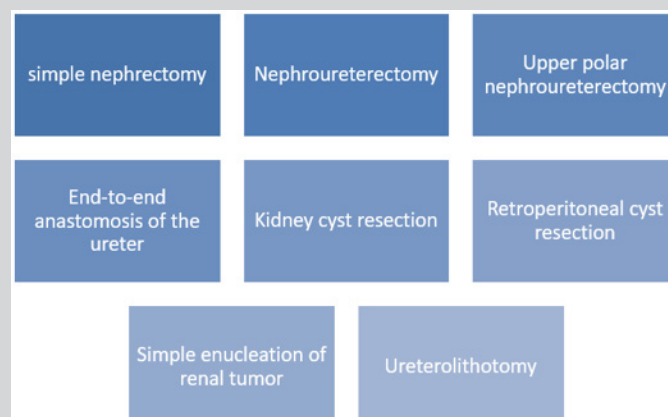


Figure 2: Main surgical procedures implemented through the lumboscopic approach.

## DISCUSSION

A retrospective review study of all children who underwent lumboscopic-assisted pyeloplasty by Minu et al. This study included a total of 96 children aged between 3 months and 10 years at the time of the operation. It is concluded that this approach can be performed safely with minimal retroperitoneal dissection, excellent cosmetic results, and minimal postoperative pain in children with pushing. In addition to that it has a shorter learning curve compared to laparoscopic pyeloplasty [20]. Another study conducted by Neerja compares two essential surgical procedures among urological surgeries, surgical intervention with the retroperitoneal versus transperitoneal approach, concluding that the selection of the type of procedure depends on the preference of the surgeon. The retroperitoneal approach can lead to increased CO<sub>2</sub> absorption, elevated PAP, a gradual increase in cerebral blood flow velocity, and decreased analgesic consumption [21]. As we have well presented, there are various surgical procedures for different urological conditions, but we want to highlight the importance of the lumboscopic approach, since it is the procedure that presents fewer side effects after its completion. A strength of the current study is the implemented methodology, regarding the literature search, and steps in the selection of relevant articles, quality assessment and data extraction. However, further analyzes of clinical trials are still required in order to compare the lumboscopic approach vs. other urological surgical approaches.

## CONCLUSION

Urological surgery during the pandemic was also affected, due to the cancellation of elective surgeries to free up healthcare resources, as well as prioritizing other surgeries. The prioritization of surgeries that occurred in the COVID-19 pandemic are bladder cancer surgery, testicular cancer, kidney cancer, among others. As is known, the lumboscopic approach had its indications since 1999, in the National Center for Minimal Access Surgery, but it was not yet fully applied in health centers, but it was since 2012, where a study was carried out where the feasibility of such access was demonstrated. Currently, the lumboscopic approach has many therapeutic indications for various diagnoses, the most frequent being retroperitoneal cysts, renal cysts, and ureteral lithiasis.

## REFERENCES

- Coffin A, Boulay CI, Sebbag SD, Zins M (2015) Radioanatomy of the retroperitoneal space. *Diagn Interv Imaging* 96: 171-186.
- Sharma G, Shreshtha S, Bhatt S, Garg PK (2019) Retroperitoneal cystic mass: a diagnostic challenge. *ANZ J Surg* 89: E576-E577.
- Rediger C, Guerra LA, Keays MA, Wayne C, Reddy D, et al. (2019) Renal cyst evolution in childhood: a contemporary observational study. *J Pediatr Urol* 15(2): 188.e1-188.e6.
- Subramanian S, Ahmad T (2021) Polycystic kidney disease of childhood. StatPearls Publishing, Treasure Island (FL).
- Malekshahi T, Khoshdel Rad N, Serra AL, Moghadasali R (2019) Autosomal dominant polycystic kidney disease: Disrupted pathways and potential therapeutic interventions. *J Cell Physiol*. 234(8): 12451-12470.
- Ferro F, Vezzali N, Comploj E, Pedron E, Di Serafino M, et al. (2019) Pediatric cystic diseases of the kidney. *J Ultrasound* 22(3): 381-393.
- Ziemba JB, Matlaga BR (2017) Epidemiology and economics of nephrolithiasis. *Investig Clin Urol* 58(5): 299-306.
- Meltzer AC, Burrows PK, Wolfson AB, Hollander JE, Kurz M, et al. (2018) Effect of tamsulosin on passage of symptomatic ureteral stones: a randomized clinical trial. *JAMA Intern Med* 178(8): 1051-1057.
- American College of Surgeons. COVID-19: Recommendations for management of elective surgical procedures 2020.
- Chan MC, Yeo S, Lee Y, Yee ML (2020) Stepping forward: urologists' efforts during the COVID-19 outbreak in Singapore. *Eur Urol* 78(1): e38-e39.
- Boeri L, Soligo M, Frank I, Stephen AB, Thompson RH, et al. (2019) Delaying radical cystectomy after neoadjuvant chemotherapy for muscle-invasive bladder cancer is associated with adverse survival outcomes. *Eur Urol Oncol* 2(4): 390-396.
- Semerjian A, Milbar N, Kates M, Michael AG, Hiten Dp, et al. (2018) Hospital charges and length of stay following radical cystectomy in the enhanced recovery after surgery era. *Urology* 111: 86-91.
- Radadia KD, Farber NJ, Tabakin AL, Wei W, Hireen VP, et al. (2019) Effect of alvimopan on gastrointestinal recovery and length of hospital stay after retroperitoneal lymph node dissection for testicular cancer. *J Clin Urol* 12(2): 122-128.
- Klaassen Z, Hamilton RJ (2019) The role of robotic retroperitoneal lymph node dissection for testis cancer. *Urol Clin North Am* 46(3): 409-417.
- Murphy C, Abaza R (2020) Complex robotic nephrectomy and inferior vena cava tumor thrombectomy: an evolving landscape. *Curr Opin Urol* 30(1): 83-89.
- Loeb S, Folkvaljon Y, Robinson D, Danil VM, Ola B, et al. (2016) Immediate versus delayed prostatectomy: Nationwide population-based study. *Scand J Urol* 50(4): 246-254.
- Strother MC, Michel KF, Xia L, McWilliams K, Thomos JG, et al. (2020) Prolonged length of stay after robotic prostatectomy causes and risk factors. *Ann Surg Oncol* 27(5): 1560-1567.
- McAdams DMMA, King EA, Luo X, Christine H, Sandra DB, et al. (2017) Frailty, length of stay, and mortality in kidney transplant recipients: a national registry and prospective cohort study. *Ann Surg* 266(6): 1084-1090.
- Srivastava A, Sureka SK, Vashishtha S, Agarwal S, Ansari MS, et al. (2016) Single-centre experience of retroperitoneoscopic approach in urology with tips to overcome the steep learning curve. *J Minim Access Surg* 12(2): 102-108.
- Minu B, Kashish K, Vikram K, Prabhu G, Dalim KB (2020) Lumboscopic-assisted pyeloplasty: a single-port, retroperitoneoscopic approach for children with pelvi-ureteric junction obstruction. *J Indian Assoc Pediatr Surg* 25(3): 163-168.
- Neerja B (2015) Retroperitoneal versus transperitoneal approach for nephrectomy in children: Anesthetic implications. *J Anaesthesiol Clin Pharmacol* 31(1): 25-26.