

# Clear Cell Carcinoma with Neck Metastasis: A Case Report

**Fred Delgado Ricardo<sup>1\*</sup>, Juan Tafur Delgado<sup>2</sup>, Alba Vellojin Olivares<sup>3</sup>, Mauricio Meza Delgado<sup>4</sup>, Luis Meza Delgado<sup>5</sup> and Juan Farak Gómez<sup>6</sup>**

<sup>1</sup>Department of Radiology resident, Military medical center, Guatemala

<sup>2</sup>Department of Pediatric resident, University of Sinú, Colombia

<sup>3</sup>Department of Pediatric resident, University of Sinú, Colombia

<sup>4</sup>Rafael Núñez University Corporation, Colombia

<sup>5</sup>Faculty of Medicine, Universidad del Sinú, Colombia

<sup>6</sup>GINUMED Group, Rafael Núñez University Corporation, Colombia

## ABSTRACT

Clear cell carcinoma represents only 3% of all adult malignant tumors worldwide and when we include single metastases to the neck, we find an incidence of only 0.09% -0.4%. Only isolated anecdotal cases have been reported in the literature. The objective of presenting this case is to describe the clinicopathological manifestations, as well as the diagnosis of metastases to a very rare site in clear cell renal carcinoma. We present the case of a 64-year-old female patient, of Guatemalan nationality, with a personal history of kidney stones, acute kidney injury 2 years ago, bilateral grade III venous insufficiency, chronic hypokalemias for 15 years and a family history of breast cancer (mother), cervical cancer (grandmother), pulmonary fibrosis (father). Currently, the treatment of clear cell renal cell carcinoma metastases is primarily palliative; however, there are new molecular targeted agents that have shown promising results as adjunctive therapy.

**KEYWORDS:** Clear cell carcinoma; Metastasis and neck

## INTRODUCTION

Clear cell carcinoma represents only 2% to 3% of all cancers, it occurs in a male-to-female ratio of 1.5: 1 in males over females, and the highest incidence occurs between the ages of 60- and 70-year-old. In 30% of cases there is a history such as smoking, obesity and high blood pressure. One third of patients will present with metastatic disease at the time of diagnosis and more than half will experience a relapse after treatment of the primary lesion [1].

Regarding the clinical manifestations, many renal masses are asymptomatic and not palpable until the last stages of the disease. Currently, more than 50% of clear

cell carcinomas are detected incidentally using imaging tests to investigate a variety of nonspecific symptom complexes [2].

Radical nephrectomy is the only relatively curative treatment option and provides approximately 96% 5-year survival for stage I patients and only 23% for patients with advanced disease or stage IV.

The most common sites of metastasis are the lung (50%), lymph nodes (35%), liver (30%), bone (30%), and adrenal glands (5%). The neck is an extremely rare site of metastasis, accounting for only 0.09% -0.4% [3].

### Quick Response Code:



**Address for correspondence:** Fred Delgado Ricardo, Department of Radiology resident, Military medical center, Guatemala

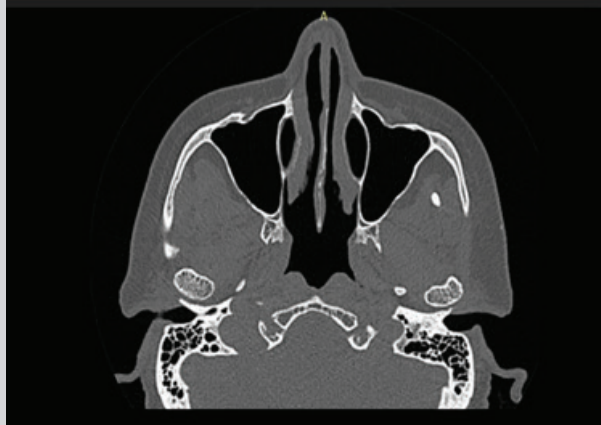**Received:** April 23, 2021      **Published:** May 21, 2021

**How to cite this article:** Fred DR, Juan TD, Alba VO, Mauricio MD, Luis MD, etc. Clear Cell Carcinoma with Neck Metastasis: A Case Report. 2021- 3(3) OAJBS.ID.000284. DOI: [10.38125/OAJBS.000284](https://doi.org/10.38125/OAJBS.000284)

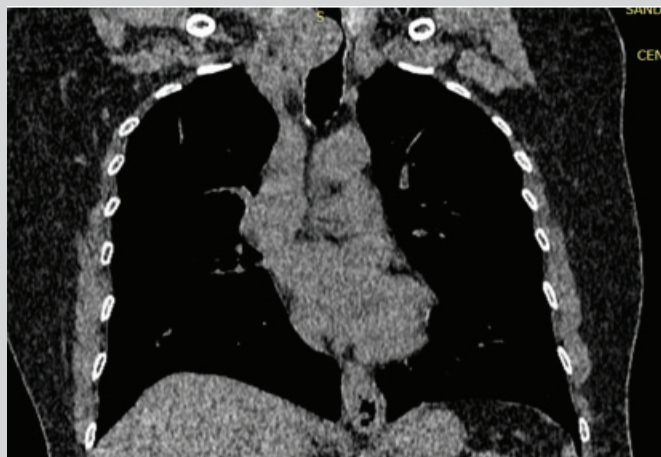## PRESENTATION OF THE CASE

64-year-old female patient, of Guatemalan nationality, who presented hemoptysis, in number of four episodes of approximately 5cc, accompanied by episodes of dry cough, dyspnea, no fever, no self-medication, which is why she consulted the emergency service, was left under observation for later discharge with outpatient management, she consulted the emergency service again for

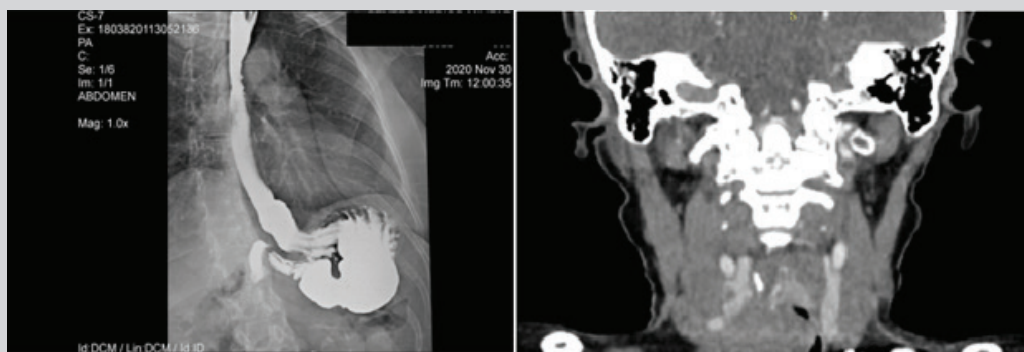
presenting a new picture of hemoptysis without improvement to outpatient treatment. An appointment with otorhinolaryngology and a paranasal sinus tomography was scheduled, which was evidenced (Figure 1). Otorhinolaryngology indicated outpatient management with rupax, steroids + antihistamines in nasal spray and nasal washes, in addition to referral for consultation with pulmonology and performance of a chest computed tomography, which was evidenced (Figure 2).



**Figure 1:** Paranasal sinus tomography: right mucoperiosteal thickening is seen, as well as nasal septum deviated to the left.



**Figure 2:** An incidental finding at the level of the neck is visualized as an image of soft tissues, which extends to the mediastinum, findings suggestive of goiter versus thyroid carcinoma. esophageal neoplastic is not ruled out.



**Figure 3:** The esophagram shows areas of stenosis or filling defects in their interior and the tomography shows thyroid masses: goiter vs carcinoma and a finding suggestive of right upper paratracheal adenopathy. A 60% area of tracheal stenosis can be seen.

Pulmonology decided to admit the patient to carry out extension studies given the findings found in the tomography, after admission the patient began with respiratory distress and did not improve with respiratory therapy, so an esophagogram was indicated to rule out esophageal obstruction or invasion and a neck CT scan with contrast medium. It is evident (Figure 3). Patient was transferred to intensive care; for presenting deterioration of his respiratory pattern, for which an emergency tracheostomy + biopsy was performed due to the risk of ventilatory failure; secondary to mass due to significant tracheal stenosis (78%). The biopsy reported clear cell carcinoma and Immuno-histochemistry revealed a tumor in the trachea compatible with metastasis of primary renal clear cell carcinoma, for which the patient was released after improvement in his respiratory pattern.

## DISCUSSION

The high frequency with which clear cell carcinoma is diagnosed in advanced stages is of great importance, if we consider that in these circumstances survival varies from three months to one year; with less than 5% over five years due to their lack of response to current treatment schemes [4]. Within this area, it is important to consider that cases with solitary metastases are only diagnosed between 1.6 and 3.6%. Surgical resection of these lesions favors the possible control of the disease and thus improvement in survival [5].

The way clear cell carcinoma metastasizes follows a relatively regular pattern to the lung, lymph nodes, and bone, as well as to less common sites: brain, liver, and pancreas. But it can also spread to other sites, which has led to its being called "internist's cancer". These sporadic locations include: soft tissues, thyroid, larynx, eye, breast, umbilical scar, ear, tongue, trachea, tonsil, esophagus, intestine, gallbladder, paranasal sinuses, diaphragm, parathyroid, hand and skin [6]. Chemotherapy is not indicated in this disease because, globally, the various schemes have a response of less

than 6%. Resistance to radiotherapy has also been observed, since extremely high doses of radiation are required, which are not tolerated due to their side effects, reserving their use only for palliative purposes [7].

## CONCLUSION

In conclusion, with this work we show evidence of a single case of metastatic neck disease, for which we advise when a diagnosis of clear cell carcinoma is diagnosed to carry out a complete physical examination and provide comprehensive therapy.

## REFERENCES

1. Muglia VF, Prando A (2015) Carcinoma de células renais: classificação histológica e correlação com métodos de imagem. *Radiol Bras* 48(3): 166-174.
2. Corbalán VR, Ruiz MJA, Brufau C, López LJM, Martínez BE, Carapeto FJ (2009) Clear cells in cutaneous squamous cell carcinoma. *Actas DermoSifiliogr* 100(4): 307-316.
3. Senra AL, Odriozola GA, Matos LE, Morales WA (2011) Carcinoma renal de células claras en riñón ectópico presacro. *Revista Cubana de Medicina* 50(3): 333-337.
4. Fernández RP, Ruiz LP, Ramírez NMA, Fuentes SA, Toussaint CS, et al. (2015) Metástasis cutánea de carcinoma de células renales (MCCCR): reporte de caso y revisión de la literatura. *Gaceta Médica de México* 151(4): 533-537.
5. Folch JJM, Cuervo DG, Jiménez JV, Marichal BA, Álvarez AJ, et al. (2015) Carcinoma de células renales: hipernefoma. Presentación de un caso. *Revista Médica Electrónica* 37(3): 279-287.
6. Altamirano R, Marín M, Staig P, Nazzal O, Suarez E, et al. (2018) Endometriosis y carcinoma de células claras. Reporte de caso. *Revista chilena de obstetricia y ginecología* 83(2): 199-202.
7. Matute G, Raigoza O, Bertel D (2018) Carcinoma de células claras renales metastásico a mama. *Revista Colombiana de Cirugía* 33(3): 311-317.